

Contractures and Drug Abuse

Srikumar V, S Wadhwa, U Singh, SL Yadav, G Handa

Department of PMR, AIIMS, New Delhi

Abstract

Contracture is limitation of complete range of motion, active or passive, due to joint, muscle or soft-tissue limitations. Myogenic contractures can be due to trauma, inflammation, degenerative changes, ischemia, and spasticity. A 32-year-old patient presented with complaints of inability to sit on the floor and limitation of multiple joint movements which progressed over the past three years. He had a history of multiple drug injections (pentazocine) for the past six years at multiple sites throughout the body. He was started on narcotic analgesics for chronic abdominal pain following pancreatitis. Deltoid, quadriceps, hamstring and calf muscles were indurated and contracted. Bilateral winging of scapula was present. Contractures are commonly associated with joint diseases; but normal radiographs and indurated muscles support a myogenic pathology in this case. Myogenic contracture due to parenteral narcotic abuse is a rare entity.

Key words: Contracture, Pentazocine, Substance-Related Disorders

Introduction

Contracture is the lack of full active or passive range of motion due to joint, muscle, or soft-tissue limitations.

Authors and their Affiliations

Dr Srikumar Venkataraman, MBBS, MD, Senior Resident
Department of Physical Medicine and Rehabilitation (PMR), All India Institute of Medical Sciences (AIIMS), New Delhi
Dr Sanjay Wadhwa, MBBS, DPMR, DNB (PMR), Additional Professor, Department of PMR, AIIMS, New Delhi
Dr U Singh, MBBS, DPMR, DNB (PMR), Professor and Head, Department of PMR, AIIMS, New Delhi
Dr SL Yadav, MBBS, MD, DNB (PMR), Associate Professor, Department of PMR, AIIMS, New Delhi
Dr Gita Handa, MBBS, MD, Associate Professor, Department of PMR, AIIMS, New Delhi

Bibliography

Srikumar V, Wadhwa S, Singh U, Yadav SL, Handa G. Contractures and Drug Abuse. IJPMPR 2009; 20 (1): 34-35.

Correspondence

Dr Srikumar Venkataraman
Department of Physical Medicine and Rehabilitation (PMR),
All India Institute of Medical Sciences
New Delhi 110 029-02

Phone: +91 9868308196 Fax +91 11-26588663

Email: vsri21@yahoo.co.in

Contractures have major impact on mobility, activities of daily living, and nursing care of skin. They cause increased energy consumption in ambulation, difficulties in dressing, grooming, eating and hygiene. Myogenic contractures are due to trauma, inflammation, degenerative changes, ischemia, spasticity and mechanical factors. Myogenic contracture due to parenteral narcotic abuse is a rare entity. One such case was reported by Das et al.¹

Case Report

A 32-year-old male patient presented with complaints of abnormal posture, inability to squat, and difficulty in some activities of daily living. He had progressive restriction of movement around both the shoulders, elbows, hips and ankle joints for the past 3 years. Restriction of movement started at all the joints at about the same time. He had no muscle weakness within the available range of motion. He had been addicted to injection of Fortwin (pentazocine) for the past 6 years. He used to take several injections of pentazocine every day. The sites of injections were bilateral shoulders, arms, buttocks, thighs and calf muscles. He had a history of alcohol dependence for the past 10 years, and history of tobacco abuse for the past 18 years. He had past history of chronic pancreatitis, pseudocyst of pancreas, splenic artery aneurysm, pulmonary tuberculosis, and diabetes mellitus. Due to pancreatitis, he had chronic abdominal pain for which he was initially prescribed and given pentazocine injection by the medical practitioners but he continued taking this drug on his own and got addicted to this.

Physical examination revealed a moderately-built man standing with abducted shoulders, flexed elbows, flexed and abducted hips and flexed knees (Fig 1). He walked with a broad based gait with decreased step length. He had multiple puncture marks throughout the body, more

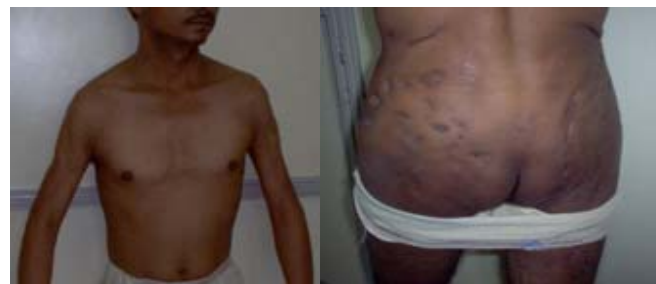

Fig 1. Arms resting in abduction due to deltoid contracture.

Fig 2. Multiple puncture marks, right buttocks smaller than left.

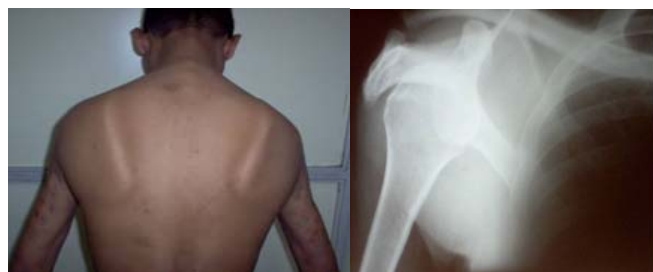

Fig 3. Winging of scapula due to deltoid contracture. Fig 4. Radiograph of shoulder joint was normal

so around the hips and shoulders (Fig 2). He had bilateral winging of scapula (Fig 3) and indurations of the deltoids, biceps, glutei, quadriceps, and gastro-soleus. Range of motion, which were abnormal, were as follows: bilateral shoulder abduction 35°-180°, right elbow flexion 0°-55°, left elbow flexion 0°-65°, right hip flexion 0°-45°, and left hip flexion 0°- 50°. Terminal flexion was mildly restricted in bilateral knees. Ankle flexion and dorsiflexion were restricted on both sides allowing a range of motion of around 25°. Distal joints were normal. Muscle power was normal. There was a mild sensory deficit in bilateral foot (stocking pattern).

Laboratory studies revealed the following values: hemoglobin 12.0 g/dl; PCV 33%; RBC $3.56 \times 10^6/\text{mm}^3$; white cell count $7200/\text{mm}^3$ (neutrophils 70%, lymphocytes 27%, eosinophils 2%, monocytes 1%); platelets $412 \times 10^3/\text{mm}^3$; erythrocyte sedimentation rate 55 mm 1st hour; blood sugar (random) 294 mg%; serum urea 14 mg%; serum creatinine 0.6mg%; uric acid 4.2 mg%; aspartate transaminase (SGOT) 22 U/l; alanine transaminase (SGPT) 15 U/l; alkaline phosphatase 87 U/l; creatine kinase 51 IU. Hepatitis B and HIV tests were negative.

Radiography revealed normal joint architecture and multiple areas of calcification at L1 due to chronic pancreatitis (Fig 4-6).

The patient received active and passive stretching exercises for muscles around the shoulder, elbow, hip, knee and ankle joints. He was started on a drug rehabilitation program at the same time. At 6 weeks follow-up there was a minimal increase in the range of motion at all joints. Later on the deaddiction program, under the department of psychiatry, however failed as the patient was lost to follow up.

Discussion

Contractures are commonly associated with joint diseases; but normal radiographs and indurated muscles support a myogenic pathology in this case. Winging of scapula was found to be due to deltoid contracture. Normal CPK value ruled out ongoing muscle destruction.

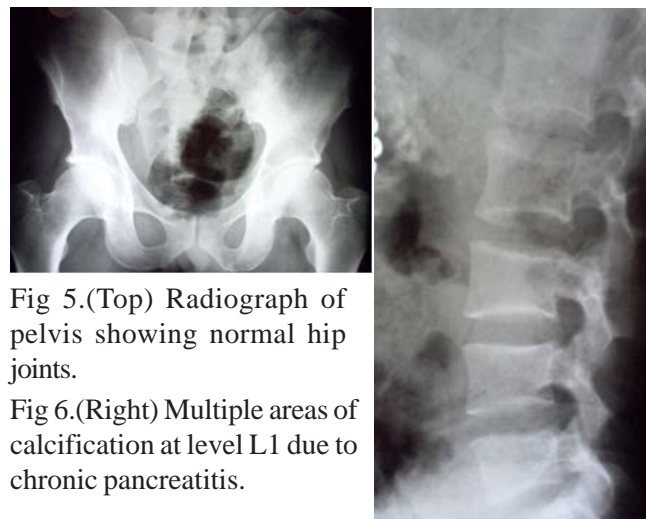


Fig 5.(Top) Radiograph of pelvis showing normal hip joints.

Fig 6.(Right) Multiple areas of calcification at level L1 due to chronic pancreatitis.

In this case, contracture had been induced by pentazocine abuse. It has been proposed that pentazocine precipitates in extracellular tissue resulting in inflammation.² Fibrosis, endarteritis, vascular thrombosis, granulomatous inflammation and fat necrosis are known histopathological changes seen in muscles after chronic use of parenteral pentazocine.³ Surgical release of contractures may have to be contemplated in cases such as this which respond poorly to stretching exercises.

Management of chronic pain with parenteral narcotic agent like pentazocine is a common practice. Pentazocine has been known to cause sclerotic ulcers and myopathy in chronic use. Contracture, as a complication, must be considered and patients must be advised to do range of motion exercises before the condition ensues. Monitoring the patients for addiction and physical examination including the range of motion of joints become important in this clinical setting.

Pentazocine abuse is a growing problem in the society⁴ and hence history of drug abuse is a must for all patients reporting with localized contractures.

References

1. Das CP, Thussu A, Prabhakar S, Banerjee AK. Pentazocine-induced fibromyositis and contracture. *Postgrad Med J* 1999; 75 (884):361-2.
2. Schlicher JE, Zuehlke RL, Lynch PJ. Local changes at the site of pentazocine injection. *Arch Dermatol* 1971; 104(1): 90-1.
3. Palestine RF, Millns JL, Spigel GT, Schroeter AL. Skin manifestation of pentazocine abuse. *J Am Acad Dermatol* 1980; 2 (1): 47-55.
4. Ray R. Current extent and pattern of drug abuse. In: Ray R (Ed). *South Asia drug demand reduction report*. New Delhi. United Nations international drug control programme regional office for South Asia ;1998: 6-31